

A Rare Cause of Intestinal Pseudo-obstruction: Colonic Amyloidosis

© İsmet Çelik¹, © Aydın Aktaş², © Burcu Kemal Okatan³

¹University of Health Sciences Turkey, Kanuni Training and Research Hospital, Clinic of Surgery, Trabzon, Turkey

²University of Health Sciences Turkey, Kanuni Training and Research Hospital, Clinic of Gastrointestinal Surgery, Trabzon, Turkey

³University of Health Sciences Turkey, Kanuni Training and Research Hospital, Clinic of Pathology, Trabzon, Turkey

ABSTRACT

Intestinal amyloidosis is a rare entity. A 78-year-old male patient presented to the emergency department with complaints of abdominal pain, nausea, vomiting and inability to pass gas/stool for five days. The patient had a history of weight loss and had attended hospital on multiple occasions for ileus. Ileus in the bowel and mass in the sigmoid colon were detected on computed tomography. Anterior resection and end colostomy were performed. Pathological examination revealed amyloid involvement in the sigmoid colon. Intestinal amyloidosis should be considered in patients with long-term and recurrent symptoms. Surgical treatment should be performed in complicated patients.

Keywords: Amyloidosis, acute abdomen, ileus, surgery

Introduction

Intestinal pseudo-obstruction is an urgent clinical condition. Intestinal pseudo-obstruction may be accompanied by abdominal pain, nausea, vomiting, inability to pass stool, and abdominal distension. Amyloidosis, which is a systemic disease characterized by the accumulation of amyloid protein in the tissues/organs is a rare cause of intestinal pseudo-obstruction.^{1,2} Amyloidosis alters intestinal function by involvement of the myenteric plexus and vascular structures in the gastrointestinal system and may lead to pseudo-obstruction.³ Conservative approaches are usually preferred in its treatment. However, in some cases, it may cause acute abdomen that requires emergency surgery.⁴⁻⁶

Herein, we present a patient in whom emergency surgery was performed due to localized amyloidosis affecting the sigmoid colon.

Case Report

A 78-year-old man presented to the emergency department with complaints of diffuse abdominal pain, nausea, vomiting, and inability to pass gas and stool for five days. There was no

history of systemic disease or surgery in his history. However, the patient had a history of weight loss and had attended the hospital on multiple occasions for ileus attacks in the last one year. Physical examination revealed diffuse tenderness, abdominal distension, and a reduction of bowel sounds. There was no stool on rectal examination. Biochemical analysis revealed anemia (9.4 g/dL), leukopenia (2300/μL) and hypoalbuminemia (2.5 g/dL). Preoperative endoscopy was not performed. On abdominal computed tomography (CT) imaging there was dilatation and edema in the small intestine, and segmental wall thickness in the large bowel (Figure 1a). The patient was taken to emergency surgery with the pre-diagnosis of acute abdomen. On exploration, there was the accumulation of about 500 cc serous-like fluid in the abdominal cavity, a gangrenous obstructed mass in the 10 cm segment of the sigmoid colon, and dilatation (up to 8 cm) in the colon segments proximal of the mass (Figure 1b). An anterior resection and end colostomy was performed. Amyloid deposition was detected in the vascular and neural structures on histopathological examination of the colon specimen (Figure 2). However, subgroup typing could not be done for technical reasons. Systemic scanning was performed



Address for Correspondence: Aydın Aktaş MD,
University of Health Sciences Turkey, Kanuni Training and Research Hospital, Clinic of Gastrointestinal Surgery, Trabzon, Turkey
E-mail: aydinaktas2004@gmail.com ORCID ID: orcid.org/0000-0003-3407-0210
Received: 15.08.2021 Accepted: 26.08.2021

in the patient, and a multiple myeloma was detected in his bone marrow. Chemotherapy (cyclophosphamide and dexamethasone) was started. Our patient was in the postoperative 3rd year his general condition was good.

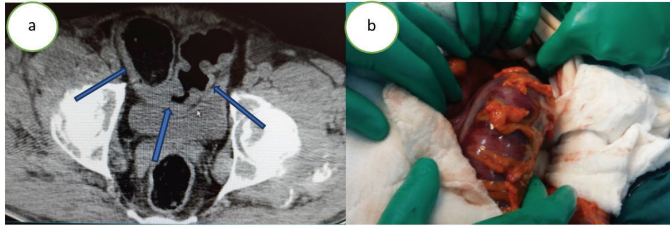


Figure 1. (a) Segmental wall thickness at the sigmoid colon on computed tomography; (b) Intra-operative view of the colon

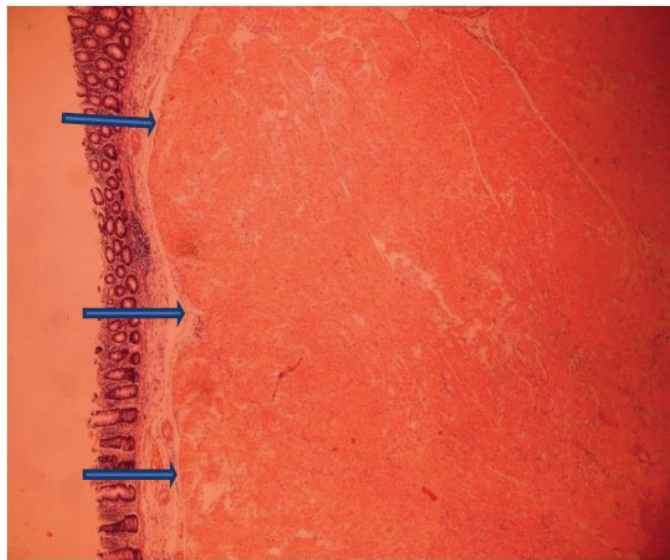


Figure 2. Accumulation of amyloid protein in the colon tissue staining orange (congo red; x4 magnification)

Discussion

Intestinal pseudo-obstruction is divided into three types according to the clinical course: Chronic intestinal pseudo-obstruction; Ogilvie's syndrome; and toxic megacolon.⁷ When symptoms last longer than six months, the disease is defined as chronic intestinal pseudo-obstruction.⁸ Intestinal pseudo-obstruction is divided into primary and secondary, according to etiology. Amyloidosis is one of the common reasons for secondary intestinal pseudo-obstruction.⁹ It usually involves the large intestine but the small intestine may be involved.⁷ There are two main subtypes of amyloidosis: Amyloidosis A (AA) and monoclonal immunoglobulin light chains amyloidosis (AL). While 15% of AL patients have multiple myeloma, AA patients are associated with chronic inflammatory, infectious, and neoplastic diseases.¹⁰ In terms of intestinal manifestation, AL amyloidosis usually presents with constipation, mechanical obstruction, or chronic

intestinal pseudo-obstruction, while AA amyloidosis presents with diarrhea and malabsorption.¹¹ In addition, when amyloid protein involvement of vascular structures of the intestine occur, it may be cause hemorrhage and hematoma.¹² Gastrointestinal involvement is mostly seen in the AA type.¹⁰ The patient in the present case had findings of ileus, and he had applied to the emergency department with similar complaints many times in the course of the previous year. However, hemorrhage was not observed in this patient. Gastrointestinal amyloidosis usually includes non-specific symptoms, and thus its diagnosis can be difficult.¹² Imaging methods and endoscopy can be useful. Plain X-rays may reveal paralytic ileus and “double halo” appearance may be present on CT.¹³ Preoperative endoscopy was not performed in the present case, since the mass in the sigmoid colon was considered the primary neoplasm of the colon. There was mass in the sigmoid colon, and dilatation at proximal colon and small intestine on CT.

The aim of treatment of amyloidosis is to reduce the formation of amyloidogenic proteins that cause dysfunction in the organ/tissues. For this, the first-line recommended treatment is combination chemotherapy regimens that include high-dose chemotherapy, such as melphalan and dexamethasone, and hematopoietic stem cell transplantation. Prokinetic agents, parenteral nutrition and anti-diarrheal agents as supportive measures can be beneficial.¹⁴ Complications due to amyloidotic involvement of the colon are very rare. Colectomy may be required in some cases.^{4,6} Here, we report a case in which anterior resection and end-colostomy was performed with a preliminary diagnosis of acute abdomen, secondary to a primary neoplasm of the sigmoid colon. For this reason, chemotherapy was given in the postoperative period.

Conclusion

It should be kept in mind that colonic obstruction due to amyloidosis may develop in the colon and these patients may require emergency surgery. Therefore, secondary causes should be considered and further investigations should be performed in the patients with signs of pseudo-obstruction in the colon.

Ethics

Informed Consent: Written informed consent was obtained from patient who participated in this case.

Peer-review: Externally peer-reviewed.

Authorship Contributions

Surgical and Medical Practices: İ.Ç., A.A., B.K.O., Concept: İ.Ç., A.A., B.K.O., Design: İ.Ç., A.A., B.K.O., Data Collection or Processing: İ.Ç., A.A., B.K.O., Analysis or Interpretation:

İ.Ç., A.A., B.K.O., Literature Search: İ.Ç., A.A., B.K.O., Writing: İ.Ç., A.A., B.K.O.

Conflict of Interest: No conflict of interest was declared by the authors.

Financial Disclosure: The authors declared that this study received no financial support.

References

1. Kumar SS, Appavu SS, Abcarian H, Barreta T. Amyloidosis of the colon. Report of a case and review of the literature. *Dis Colon Rectum* 1983;26:541-544.
2. Rewitzer H, Wegmann W, Stotz R. Intestinal pseudoobstruction in primary amyloidosis of the intestinal tract. *Schweiz Med Wochenschr* 1984;114:1886-1890.
3. Kim YJ, Kim HS, Park SY, Park SW, Choi YD, Park CH, Choi SK, Rew JS. Intestinal amyloidosis with intractable diarrhea and intestinal pseudo-obstruction. *Korean J Gastroenterol* 2012;60:172-176.
4. Dörner O, Tolksdorff G, Gamstatter G, Bettendorf U, Schmidt H. Solitary primary amyloid tumour of the rectum. *Leber Magen Darm* 1989;19:95-96.
5. Nicholl D, Jones T. Intestinal pseudo-obstruction due to amyloidosis of the colon in association with an intestinal plasmacytoma. *Postgrad Med J* 1991;67:1075-1077.
6. Rives S, Pera M, Rosiñol L, Vidal O, Miquel R, Solé M, García-Valdecasas J, Bladé J. Primary systemic amyloidosis presenting as a colonic stricture: successful treatment with left hemicolectomy followed by autologous hematopoietic stem-cell transplantation: report of a case. *Dis Colon Rectum* 2002;45:1263-1266.
7. Stanghellini V, Cogliandro RF, de Giorgio R, Barbara G, Salvioli B, Corinaldesi R. Chronic intestinal pseudo-obstruction; manifestations, natural history and management. *Neurogastroenterol Motil* 2007;19:440-452.
8. Lida T, Hirayama D, Sudo G, Mitsuhashi K, Igarashi H, Yamashita K, Yamano H, Nakase H. Chronic intestinal pseudo-obstruction due to al amyloidosis: a case report and literature review. *Clin J Gastroenterol* 2019;12:176-181.
9. Connor FL, Di Lorenzo C. Chronic intestinal pseudo-obstruction: assessment and management. *Gastroenterology* 2006;130(2 Suppl 1):S29-36.
10. Ebert EC, Nagar M. Gastrointestinal manifestations of amyloidosis. *Am J Gastroenterol* 2008;103:776-787.
11. Hokama A, Kishimoto K, Nakamoto M, Kobashigawa C, Hirata T, Kinjo N, Kinjo F, Kato S, Fujita J. Endoscopic and histopathological features of gastrointestinal amyloidosis. *World J Gastrointest Endosc* 2011;3:157-161.
12. Shiratori Y, Fukuda K, Ikeya T, Takagi K, Nakamura K. Primary gastrointestinal amyloidosis with gastrointestinal hemorrhage and intestinal pseudo-obstruction: a report of a rare case. *Clin J Gastroenterol* 2019;12:258-262.
13. Georgiades CS, Neyman EG, Barish MA, Fishman EK. Amyloidosis: review and CT manifestations. *Radiographics* 2004;24:405-416.
14. Wetwittayakhleng P, Sripongpan P, Jandee S. Primary gastrointestinal amyloidosis: An unusual cause of acute intestinal pseudo-obstruction. *Case Rep Gastroenterol* 2019;13:462-467.