

Management of Iatrogenic Perforations During Colonoscopy

Kolonoskopi Esnasında Gelişen İatrojenik Perforasyonların Tedavisi

ONUR BİRSEN¹, MURAT OZBAN¹, HALİL ERBİŞ¹, ALİ KOÇYİĞİT², UĞUR SUNGURTEKİN¹

¹Pamukkale Üniversitesi Tıp Fakültesi, Genel Cerrahi Anabilim Dalı, Denizli-Türkiye ²Pamukkale Üniversitesi Tıp Fakültesi, Radyoloji Anabilim Dalı, Denizli-Türkiye

ÖZET

Amaç: Kolon perforasyonu, rutin ya da tedavi amaçlı yapılan kolonoskopinin en korkulan komplikasyonlarından biri haline gelmiştir. Bu komplikasyonun tedavisi takip sırasında hastanın durumuna bağlıdır. Tedavi açık ya da laparoskopik acil cerrahi olabileceği gibi, konservatif de olabilir. Kolonoskopi sırasında rektal retrofleksiyonun yaralanmasın da genellikle perforasyon riski düşüktür ve yine bu hastaların tedavisi operasyon gerektirmeyebilir. Biz bu yazıda, elektif kolonoskopi sırasında meydana gelen kolon perforasyonu gelişen hastalarımızı ve tedavi yöntemlerini sunduk.

Hastalar ve Yöntemler: Aralık 2005 ile Aralık 2010 arasında kolonoskopi yapılmış hastalardan perforasyon gelişen hastalara ait bilgiler retrospektif olarak değerlendirildi. **Bulgular:** Yukarıdaki tarihler arasında 5825 hastaya kolonoskopi yapılmış, 3 hastada perforasyon

ABSTRACT

Purpose: Perforation of colon has become one of the most fearsome complications of routine or therapeutic colonoscopy. The treatment is immediate surgery via open or laparoscopic technique. However, rectal retroflexion injury during colonoscopy is associated with a low rate of perforation and the cases can be managed non-operatively. We report our series of colonic perforation due to elective colonoscopy and management of the cases.

Patients and Methods: Iatrogenic perforation of the colon due to colonoscopy were collected retrospectively at our unit between dates December 2005 - December 2010.

Results: Of the 5825 colonoscopies performed between the above mentioned dates, a perforation rate of 0.051% was observed and three perforations occurred.

Conclusion: Each treatment has to be individualized

Başvuru Tarihi: 13.01.2011, Kabul Tarihi: 24.03.2011

✉ Dr. Onur Birsen

Pamukkale Üniversitesi Tıp Fakültesi,
Genel Cerrahi Anabilim Dalı, Denizli - Türkiye

Tel: 0532.6415620

e-mail: birsenonur@yahoo.com

Kolon Rektum Hast Derg 2011;21:57-62

gelişmiş ve perforasyon oranı %0.051 olarak izlenmiştir.

Sonuç: Tedavi hastanın klinik durumuna göre planlanmalıdır. Hastanın yaşı, ko-morbilitesi, perforasyonun oluş şekli, perforasyonun yeri ve büyüklüğü, barsak temizliğinin yeterliliği, perforasyon ile tanı arasında geçen süre, yandaş kolorektal hastalıkların varlığı, kolonoskopi sırasında gelişen perforasyon tedavisinde en önemli faktörlerdir.

Anahtar Kelimeler: Kolonoskopi, Polipektomi, Perforasyon

Introduction

Colon perforation is a rare but serious complication that may be encountered during colonoscopy. Perforation site may be differ according to the causal mechanisms; direct perforation into peritoneal cavity or into the retroperitoneal space.¹ Additionally, perforation site determines the symptom diversity.²

The aim of this study was to review of our experience in the management of iatrogenic perforations due to colonoscopy. We report three cases of iatrogenic perforation of colon after colonoscopy in our endoscopy unit.

Patients and Methods

Patients

Iatrogenic perforations of the colon due to colonoscopy were collected at our unit between dates December 2005 - December 2010. Medical data were recorded retrospectively from electronic medical records and paper charts. The clinicopathological data, including gender, age, past history symptoms, physical examination, diagnostic assays, and pathological examination, length of stay and surgical information as well as outcome were analyzed to assess medical management of these patients.

Surgery

Multiple surgeons at our institution performed urgent surgical procedures but colorectal surgeries were performed by the same surgeon (US). Surgical decisions were done according to surgeon's preference and patient's clinical status.

Results

Of the 5825 colonoscopies performed between dates December 2005-December 2010, three perforations occurred with a perforation rate of 0.051%. All colonoscopies performed by the same surgeon (US).

according to patients' clinical status. Patients' age and comorbidities, nature of the perforation, size and site of the perforation, the adequacy of the bowel preparation, the time between injury and diagnosis, concomitant colorectal pathologies are the most important factors in the management of perforation during colonoscopy.

Key words: Colonoscopy, Polypectomy, Perforation

Out of three perforations, two of them were diagnostic reasons and one was for therapeutic purpose. The mean age at the time of the colonoscopy was 47,6 years. One patients had a history of ulcerative colitis, the others had polyps. We present all three patients one by one for better understanding the cause and result relationship.

Case I

A 53-year-old male patient underwent colonoscopy for a colon polyp 2.5cm in size at the descending colon, re-hospitalized on the next day because of abdominal pain. After being kept under observation for 24 hours, abdominal pain of the patient aggravated was operated on. There was a delayed perforation at the polypectomy area. In the operation, there was a local peritonitis but these was not generalized. Because of the history of familial colonic cancer and having multiple polyps in the different parts of the colon, the patient underwent total colectomy and ileorectal anastomosis. Postoperative course was uneventful.

Case II

A 38-year-old female patient admitted to our hospital because of active ulcerative colitis. She underwent immediate operation because of a perforation at sigmoid colon when peritoneal cavity was assigned during colonoscopy. Total colectomy and ileorectal anastomosis was performed. Postoperative course was uneventful.

Case III

A 52-year-old man applied to the outpatient clinics with the complaint of anal bleeding over one month. He underwent flexible sigmoidoscopy with rectum and rectosigmoid junction biopsies. Histopathological examination demonstrated a tubular adenoma with low-grade dysplasia at the rectosigmoid junction. The patient was referred to our gastroenterology unit for polypectomy and total evaluation of the colon. Patient suddenly felt

uncomfortable and complained of a sudden abdominal distension during colonoscopy in our unit, the procedure was stopped.

Physical examination revealed emphysema in the neck and chest, patient's voice was changed, his face was swollen and had abdominal distention and discomfort without tenderness and signs of peritonitis. White blood cell (WBC) count was 7000/ml. Upright plain abdominal and chest X-ray films were normal. Contrast computed tomography (CT) (with both oral and rectal routes) examination revealed large amount of air in the retroperitoneal space but no signs of peritoneal perforation and substantial retroperitoneal perforation (Fig.1).

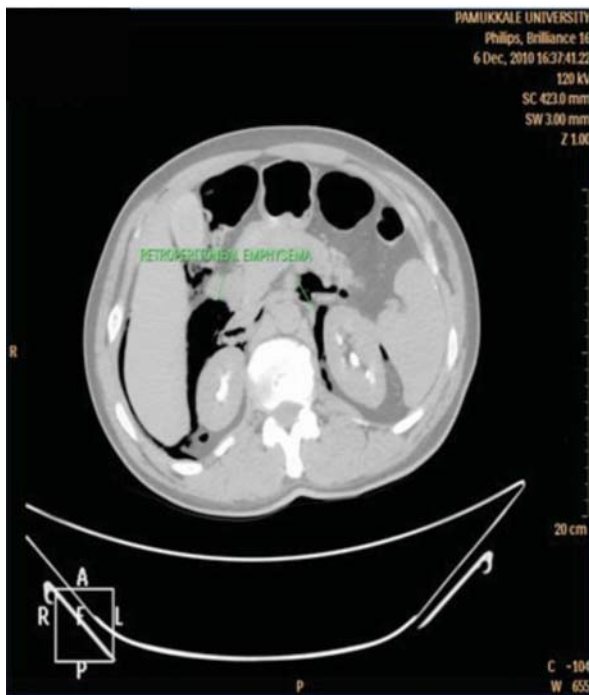

Figure 1. CT demonstrate retroperitoneal free air.

Oral intake ceased and intravenous antibiotics were given. The patient was stable, afebrile and pain free on the next day. WBC count was 11.000/ml and C-reactive protein was 10mg/dl. In the following day, suddenly the patient developed fever without abdominal tenderness with WBC count of 22.000/ml and CRP was elevated 44mg/dl. Control X-ray revealed classic pneumoperitoneum (Fig. 2). A third day follow up CT examination demonstrated peritoneal perforation (Fig. 3).

Laparotomy revealed that the perforation site was at the rectosigmoid junction (Fig. 4). Since rectovesical fossa filled with pus, Hartmann surgery preferred due to the

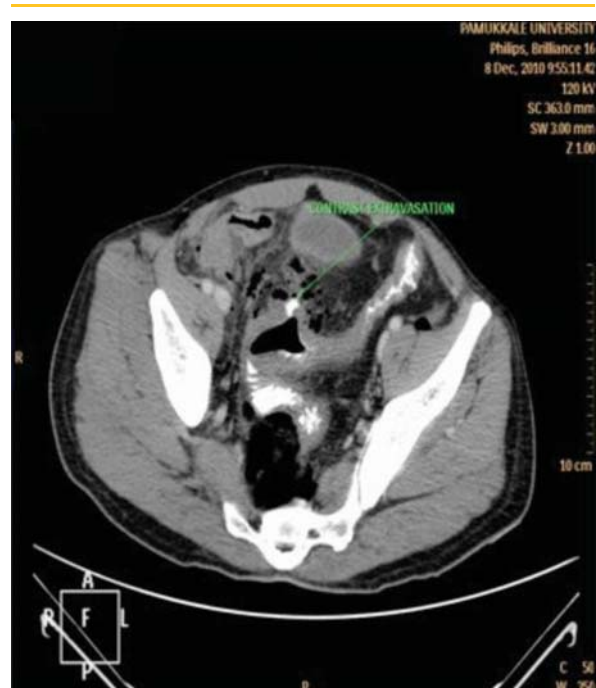

Figure 3. CT demonstrate late perforation.

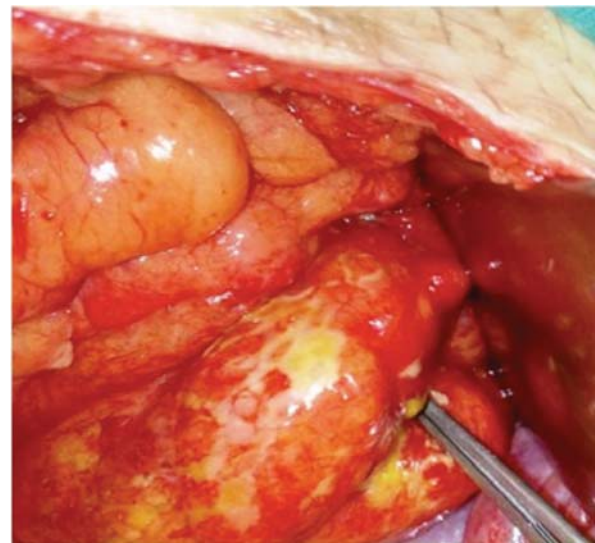


Figure 4. Perforated site was rectosigmoid colon.

condition of the patient (Fig. 5,6). Histopathological diagnosis was tubular adenoma and the patient was discharged after a week.

All patients developed abdominal discomfort and distension, which was the most consistent early symptom. Other signs were abdominal pain followed by rebound tenderness, leukocytosis, fever and tachycardia. One patients were diagnosed at time of colonoscopy and underwent immediate surgery (case-II), whereas the

other was diagnosed within 24 hours, was suspected base of signs and symptoms (case-I) and case III had delayed diagnosis after 72 hours.

Chest and abdominal radiographic examination performed in all patients and revealed free intraabdominal air except case-III. However, control chest X-ray in case-III revealed intraabdominal air due to the late perforation. Abdominal and pelvic CT examinations with water-soluble contrast were performed in case-III. In case-II perforation was suspected when a hole in the intestinal wall was noted and underwent urgent surgery without any examination. Perforation sites were at the rectosigmoid colon in two patients, where as at the descending colon in case-I. Two patients underwent subtotal colectomy and ileorectal anastomosis without a diverting stoma; case-III underwent Hartmann procedure. Pre-post-operative histopathologic results of the samples were consistent. Mean of hospital stay was 10 days (range, 7-14). There were no deaths.

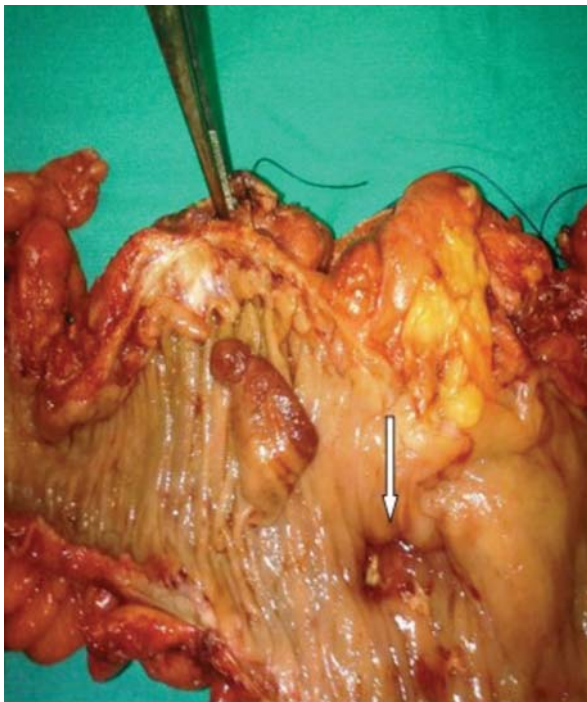


Figure 5. Delayed perforation site.

Discussion

Perforation of colon has been one of the imminent complications of routine or therapeutic colonoscopy. Although colonoscopic perforation might occurs rarely, it can be associated with high mortality and morbidity. In our center incidence of colonoscopic perforation rate was 0.051%. The incidence of perforation in the high-

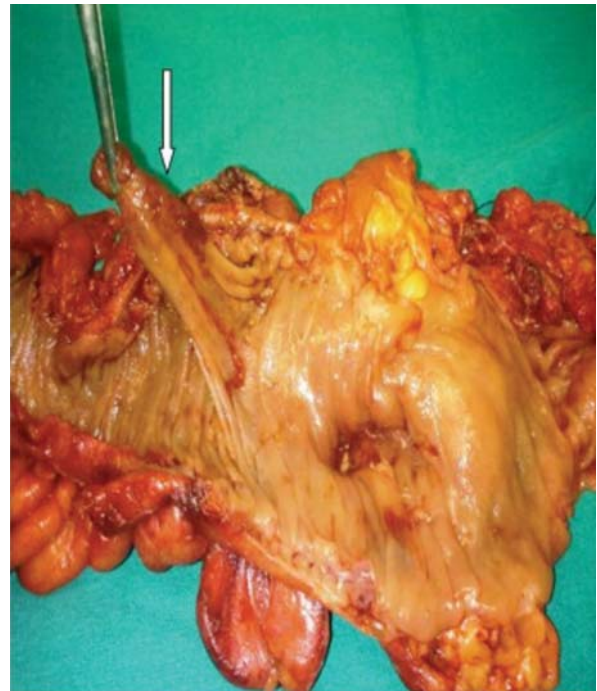

Figure 6. Pediculated tubular adenoma.

volume centers was estimated between 0.01% and 0.6%.³ The perforation risk depends also on the type of colonoscopy; diagnostic or therapeutic. Perforation risk varies from 0.03% to 0.8% at the diagnostic colonoscopy where as 0.15% to 3% at the therapeutic colonoscopy.⁴ We examined that the incidence of our perforation rates was higher in therapeutic colonoscopy. The most difficult areas to negotiate with the scope were sigmoid colon and hepatic flexure where the perforation rates were higher.⁵ In our study we found out that rectosigmoid junction was the most perforated site. It might be due to the difficulty in flexing maneuver during colonoscopy or slimming of the colonic wall due to the underlying ulcerative colitis. Direct trauma to the bowel wall, excessive air insufflations, perforation due to transmural biopsy and improper use of electrocautery during polypectomy might be the other reasons of a perforation. In addition, various conditions might predispose to perforation such as inflammatory bowel disease, diverticulitis, malignancy, previous abdominal surgery, strictures and adhesions.^{5,6} The perforation occurred in one patient with ulcerative colitis due to direct mechanical trauma to the colon wall and the underlying cause in other patients was improper use of electrocautery.

Size, site and the mechanism of perforation, the time between injury and diagnosis, the adequacy of the bowel preparation, degree of peritoneal contamination, patient's comorbidities, immunologic status and anticoagulation status are all the potential factors in the severity of the symptoms.^{7,8} Complete perforation typically causes acute abdomen with pneumoperitoneum and clinical presentation occurs with abdominal pain, distension, abdominal discomfort, sign of peritonitis, tachycardia, hypotension and even with septic shock. In these patients, upright X-rays are useful for diagnosis. Intra-peritoneal free air demonstrates perforation. The treatment of these patients must be immediate laparoscopic or open surgery. If the perforation site is smaller than fifty percent of bowel circumference, and without significant fecal contamination, and no concomitant intestinal pathology; simple closure of the perforation site can be done. Otherwise bowel resection with or without diverting stoma is required.⁸ If a perforation site noted during colonoscopy and adequate bowel preparation is done then endoscopic repair with endoclips can be useful as a treatment modality.⁹ Sometimes the patient may remain stable, afebrile and painfree, but if the upright X-ray shows free air under the diaphragm then these findings should be regarded as secondary to asymptomatic colonic perforation after a colonoscopy.¹⁰

Abdominal and pelvic CT with oral and rectal water-soluble contrasts must be performed to identify the perforation site, like formation of abscess or intraabdominal fluid and to determine peritoneal and retroperitoneal air. Because; the amount of free air on

the plain film may not be an accurate indicator of the defect's size and some cases of contained perforation can only be detected by tomographic studies, CT scans should be immediately considered.¹¹ If the patient is healthy and without any evidence of peritonitis, in the CT scan contained perforation was apparent than conservative medical management may be an alternative treatment but if the CT scan demonstrate a substantial perforation then surgery was needed again.¹¹ Incomplete perforation may lead to retroperitoneal gas accumulation, often painless and sometimes accompanied by subcutaneous emphysema, pneumomediastinum, pneumothorax, dysphagia and dysphonia. Retroperitoneal gas and subcutaneous emphysema is usually associated with rectal retroflexion perforation. In this situation, medical management may be the best alternative treatment.^{12,13} In case III we decided that the patient had an incomplete rectal perforation and initiated the medical treatment. However, probably a delayed perforation might have occurred due to the tissue necrosis so the patient underwent urgent operation.

In conclusion, each treatment has to be individualized according to patients' clinical status. Patients' age and comorbidities, nature of the perforation, size and site of the perforation, the adequacy of the bowel preparation, the time between injury and diagnosis, concomitant colorectal pathologies are the most important factors in the management of perforation during colonoscopy. If a perforation is suspected during colonoscopy, the patient should be followed carefully.

Reference

1. Tam WC, Pollard I, Johnson RD. Case report: pneumomediastinum and pneumothorax complicating colonoscopy. *J Gastroenterol Hepatol* 1996;11:789-92.
2. Ho HC, Burchell S, Morris P, *et al.* Colon perforation, bilateral pneumothoraces, pneumopericardium, pneumomediastinum, and subcutaneous emphysema complicating endoscopic polypectomy: anatomic and management considerations. *Am Surg* 1996;62:770-4.
3. Avgerinos DV, Llaguna OH, Lo AY, *et al.* Evolving management of colonoscopic perforations. *J Gastrointest Surg* 2008;12:1783-9.
4. Luning TH, Keemers-Gels ME, Barendregt WB, *et al.* Colonoscopic perforations: a review of 30,366 patients. *Surg Endosc* 2007;21:994-7.
5. Daniels IR, Sullivan T, Hale J. Retroperitoneal gas after colonoscopy. *J R Soc Med* 1999;92:21-2.
6. Tulchinsky H, Madhala-Givon O, Wasserberg N, *et al.* Incidence and management of colonoscopic perforations: 8 years' experience. *World J Gastroenterol* 2006;12:4211-3.
7. Kang HY, Kang HW, Kim SG, *et al.* Incidence and management of colonoscopic perforations in Korea. *Digestion* 2008;78:218-23.
8. Lohsiriwat V. Colonoscopic perforation: incidence, risk factors, management and outcome. *World J Gastroenterol* 2010;16:425-30.
9. Trecca A, Gaj F, Gagliardi G. Our experience with endoscopic repair of large colonoscopic perforations and review of the literature. *Tech Coloproctol* 2008;12:315-21; discussion 322.
10. Jafri SM, Arora A. Silent perforation: an iatrogenic complication of colonoscopy. *Surg Laparosc Endosc Percutan Tech* 2007;17:452-54.
11. Kavic SM, Basson MD. Complications of endoscopy. *Am J Surg* 2001;181:319-32.
12. Ballas KD, Rafailidis SF, Triantaphyllou A, *et al.* Retroperitoneal, mediastinal, and subcutaneous emphysema, complicating colonoscopy and rectal polypectomy. *J Laparoendosc Adv Surg Tech* 2008;18:717-20.
13. Akin M, Ege B, Akin FE, *et al.* Colonic stricture following conservative treatment of a colonoscopic perforation. *Endoscopy* 2008, 40 Suppl 2:E89.