

Amyand's Hernia: Report of Two Cases and a Review of the Literature

Amyand Fıtığında İki Olgu ve Literatürün Gözden Geçirilmesi

ÜMRAN MUSLU, ÖMER ARDA ÇETİNKAYA

T.C. Sağlık Bakanlığı Alaca Devlet Hastanesi, Genel Cerrahi Bölümü, Alaca, Çorum-Türkiye

ÖZET

Amyand fıtığı adlandırması inguinal fıtık kesesi içerisinde rüptüre appendiks vermiformisi tanımlamak için Claudius Amyand ilk kez appendektomi uyguladığında kullanılmaktaydı. Daha sonraları, inguinal fıtık keseleri içerisinde inflame olsun ya da olmasın appendiks vermiformis bulunması durumuna Amyand fıtığı denilmeye başlanmıştır. Fıtık defektinin kontamine alanlarda sentetik veya biyosentetik yamalar ile onarımı halen tartışmalıdır. Sağlık, esneklik, konuk doku kompatibilitesi ve enfeksiyonlardan korunma yeteneği ideal bir yamanın tanımı olmalıdır. Pek çok sentetik ve biyolojik yama dokusu tüm dünyada kullanılmasına karşın, halen tanımdaki ideal yamaya uyan ve kabul gören bir yama çeşidi bulunmamaktadır. Biz, merkezimizde ameliyat ettiğimiz iki adet Amyand fıtığı olgusunu sunmaktayız. Her iki olguda da appendektomi ve polipropilen yama ile fıtık onarımını aynı anda gerçekleştirdik. Hastaların takiplerinde nüks veya enfeksiyon varlığı saptamadık.

ABSTRACT

The designation "Amyand's" in association with a hernia is used for Amyand's name to any hernia was used for a ruptured appendix found in an inguinal hernia sac based on the recognition that Claudius Amyand was the first to perform an appendectomy. Recently, inguinal hernias containing the appendix, both inflamed and not, have been called Amyand hernia. Roughly only 0.1% of inguinal hernias contain an inflamed appendix. The repair of such defects with mesh grafts is still debatable due to unresolved suspicion of contamination. Strength, flexibility, host tissue compatibility and ability to avoid infections should characterize an ideal mesh. Many synthetic and biological mesh tissues have been proposed over time but no single material, nor newer biosynthetic mesh, has fulfilled these requirements and gained universal acceptance. We present two cases in which biological meshes were used successfully in contaminated fields. Here, we aim to report two cases diagnosed with Amyand's hernia intraoperatively at our centre. We

Başvuru Tarihi: 16.06.2011, Kabul Tarihi: 29.07.2011

✉ Dr. Önder Arda Çetinkaya

T.C. Sağlık Bakanlığı Alaca Devlet Hastanesi

Alaca Çorum - Türkiye

Tel: 0505.4828272

e-mail: omerardacetinkaya@yahoo.com

Kolon Rektum Hast Derg 2011;21:130-135

Anahtar Kelimeler: Amyand Hernia, Yama, Appendektomi

Introduction

Inguinal hernias containing the appendix, both inflamed and not, have been called Amyand hernia. Roughly only 0.1% of inguinal hernias contain an inflamed appendix. This incidence is as high 16.6% in one series, including only children. They occur most often in male patients in a bimodal age distribution (premature infants and elderly).

Amyand hernia is a special variation of inguinal hernias and repair of the hernia with mesh graft is still questionable because of the involvement of inflamed or non-inflamed appendix vermiformis. In particular, when a synthetic mesh is applied to contaminated wounds, its removal is required in 50%-90% of cases. Biosynthetic meshes are the newest tool available to surgeons and they could have a role in ventral hernia repair in a potentially contaminated field.¹

However biosynthetic meshes are still not widely available in our country. We describe the use of a polypropylene mesh graft in the reconstruction of Amyand's hernia defect in two patients. We preferred one-step operation for our patients; as we know low recurrence rate can be created of a hernia repair with mesh grafts. We decided to use grafts in the knowledge and subtypes scala of Losano and Basson.² From July 2006 to June 2011, 101 patients with the diagnosis of inguinal hernia were operated in our center, and two cases were diagnosed as Amyand hernia, intraoperatively. Both patients were in subtype two group. They had inflamed but not perforated appendix. Appendectomies were performed and then hernia repairs were done with mesh grafts. Prophylaxis and therapies of antibiotics and irrigation of the defected area were done peroperatively. However there is no consensus on usage of antibiotics in these kind of cases. We experienced no evidence of recurrence at 6 months and 2 years follow-up. Our aim is presenting two cases of Amyand's hernia which repaired with mesh grafts although both cases were in subtype two for scala of Losano and Basson. Usage of mesh graft in subtype two is still questionable;

performed appendectomy and hernia repair with polypropylene mesh graft in both cases, and there were no recurrence or infection on follow up.

Key words: Amyand Hernia, Graft, Appendectomy

these kind of cases might be helpful for a new approach.

Report of two cases

Incarcerated inguinal hernias represent a challenging problem. Repair of incarcerated inguinal hernias are mostly performed in emergency conditions. Therefore surgeons must evaluate cases and make decisions intraoperatively. Diagnosis of Amyand's hernia is not always possible before surgery. Additionally, repair of Amyand's hernia subtype 2 is still unclear. In our cases, we are presenting the results of subtype 2 which repaired with mesh graft.

The first case

A 42-year-old male patient presented at the emergency department with a 12-hour history of cramping lower abdominal pain that radiated to his groin and lower back. An initial evaluation demonstrated leukocytosis, and right lower quadrant and right groin tenderness, which prompted a surgical consult. A physical examination revealed a large, nonreducible right inguinal hernia. The patient was taken to the operating room for repair of a incarcerated hernia. The repair was completed through a right groin incision. Direct and indirect hernias were

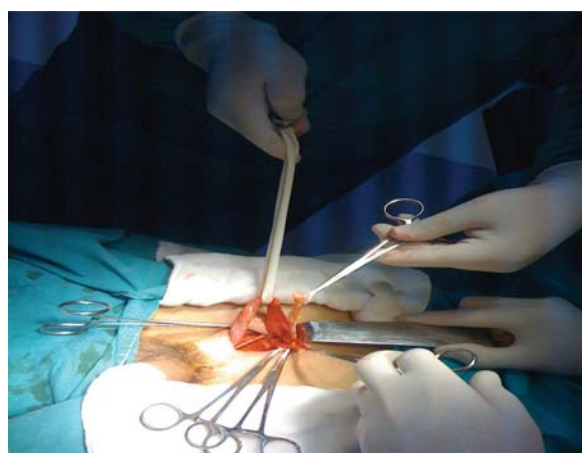


Figure 1. Spermatic cord and appendix vermiformis are seen.

identified, as was an acutely inflamed appendix without perforation (Fig. 1).

The appendix was resected through the groin incision, transverse fascia was sutured primarily and a mesh graft was used for repairing the hernia defects (Repair of Lichtenstein). The patient was discharged on postoperative day 2 without any complication. A follow-up at 2 years demonstrated no recurrent hernia.

The second case

An 76-year-old male presented at the emergency department with a history of right lower quadrant pain and nausea. Findings on physical examination included slight abdominal distention, tenderness to deep palpation in the right lower quadrant and a moderate-size right inguinal hernia. No fever or peritoneal irritation signs were noted. Leukocytosis was the only remarkable result among the laboratory tests. Diagnosis of incarcerated hernia was thus made.

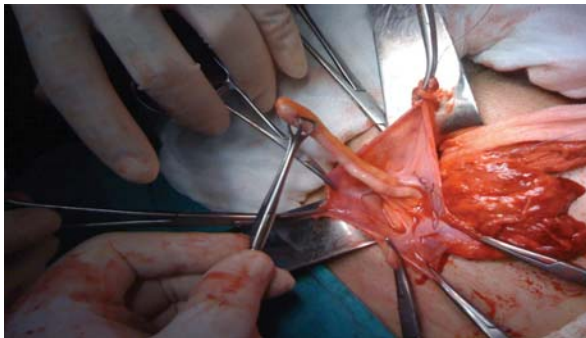


Figure 2. Appendix vermiformis is seen in the hernia sac.

The patient was taken to the operating room where laparotomy revealed appendix, mildly thickened with fecalith palpation in the lumen, and both direct and indirect right inguinal hernia defects (Fig. 2). Appendectomy was performed followed by repair of the right inguinal direct and indirect hernias with mesh graft (Repair of Lichtenstein). The postoperative course was unremarkable, and the patient was discharged home on postoperative second day. A follow-up 6 months demonstrated no recurrent hernia.

We preferred inguinal incisions in both cases because we wanted to evaluate the condition of intestines. We could not be sure of strangulation before surgery.

Discussion

In 1735, Claudius Amyand performed the first recorded appendectomy. The patient was an 11-year-old boy who had an enterocutaneous fistula due to perforation of his appendix. The contents of the hernia sac included a perforated vermiform appendix. The procedure lasted 30 minutes and consisted of an appendectomy with primary closure of the hernia defect. Amyand was noted to have remarked, "It's easy to conceive that this operation was as painful to the patient as laborious to me." Fortunately for the patient, he managed to survive the most common outcome of perforated bowel at this time: overwhelming sepsis and death. It was almost 150 years before the first appendectomy would be performed in the United States, which coincidentally was also for appendicitis in an inguinal hernia. Since that time, many case reports of these rare hernias have been published. Amyand's name to any hernia was used for a ruptured appendix found in an inguinal hernia sac based on the recognition that he was the first to perform an appendectomy. Recently, inguinal hernias containing the appendix, both inflamed and not, have been called Amyand hernia.^{3,4}

Although most papers consist of a single unique case, Kaymakci et al. published series of Amyand hernia in 2009, which consisted of 30 children with a variety of hernias containing the appendix.⁵ The incidence of an Amyand hernia is difficult to determine because of its relative rarity; however, it is often cited that approximately 1% of all hernias contain the appendix with a range of 0.28% to 1.61%, including femoral and inguinal hernias. Roughly only 0.1% of inguinal hernias contain an inflamed appendix. This incidence is as high 16.6% in one series, including only children. They occur most often in male patients in a bimodal age distribution (premature infants and elderly). Most commonly, the hernia is located on the right side because of the anatomical position of the appendix; however, it has been found on the left attributed to a highly mobile cecum. It is often mentioned that situs inversus is a cause of a left-sided Amyand hernia, but this has not been confirmed by the literature.

The incidence of herniation of the appendix is low: one large series found that only about 1% of inguinal hernias contain the organ. Inflammation or perforation of such an appendix occurs less commonly. One study of over

8000 cases of acute appendicitis found the organ in a hernia sac of any kind in only 0.13% of cases. Other variants, such as herniation of an inflamed appendix into the scrotum and into a left inguinal hernia have been reported, as has necrotizing fasciitis of the skin overlying an Amyand hernia. In addition to inguinal hernias, the appendix has been found in obturator, umbilical incisional, and femoral hernias. Femoral hernias are the second most common type, often called the De Garengeot hernia, and they are most commonly found in post-menopausal females.

Although inflammation of the appendix in its usual anatomical position is caused by obstruction of the lumen by a fecalith, inflammation in an Amyand's hernia is thought to be caused by one of 2 mechanisms. The first is a primary inflammatory process that causes edema to the surrounding structures, including the internal ring resulting in incarceration and obstruction. A second mechanism is thought to be incarceration of the normal appendix by contraction of the abdominal musculature in the inguinal canal, which is followed by inflammation of the appendix and bacterial overgrowth. No data are available to determine the risk of appendicitis in patients who have a uninflamed appendix in an inguinal hernia sac. In both mechanisms, despite occasional perforation and spillage of contaminated material into the surrounding space, peritonitis does not occur because the purulent material is contained within the hernia sac. It is to this that the survival of Amyand's first patient was attributed. The most common presenting symptom in an Amyand hernia is a painful swelling in the groin. The development of the bulge might be acute or it might have been present for many years with only the recent onset of pain. Other presenting symptoms are similar to those of appendicitis versus incarcerated or strangulated inguinal hernia. Occasionally, patients present with signs and symptoms of complete obstruction. Children might demonstrate agitation with vomiting and dehydration. On physical examination, a tender irreducible groin bulge is noted with the absence of abdominal findings, although right lower quadrant tenderness is occasionally present. Often, the patient is afebrile with no other clinical markers of disease unless the hernia is associated with intra-abdominal pathology.

On laboratory examination, there is mild leukocytosis, although the white blood cell count might be normal.^{3,4}

In our cases, both patients had leukocytosis and tenderness of groins. We diagnosed Amyand hernia intraoperatively because we did not have a chance to perform computerized tomography in our center. That was not an exact deficiency for these cases. Both patients had typical symptoms of incarcerated hernia and the route of operation or diagnosis was not effected with the lack of imaging. The most debatable account in these cases was namely our decision on a repair technique. We knew that there is no clear data and consensus on repair with grafts in suspicious contaminated areas.

There are rare case reports including repairs with synthetic and biological grafts and their results are acceptable. Rarity of Amyand hernia is a disadvantage for discussing and deciding in which conditions are suitable for grafts. However Losano Basson scala proves to be helpful in these kind of cases. In Amyand hernia subtype two, graft repair seems to be applicable as proven by adequate follow up. This recommendation abides to our cases. Additionally, developments in biomeshes will be hopeful for mesh graft usage although we used conventional polypropylen mesh grafts. Two cases are not enough to reach the right conclusions for those situations but overall results are promising that one-step repair in Amyand hernia can be valid in the future.

Preoperative Diagnosis

The diagnosis of an appendix-containing inguinal hernia is most often made at the time of operation; however, acknowledgment before initiation of the procedure is beneficial in preoperative planning. Imaging modalities include computerized tomography (CT) with oral contrast, acute abdominal film, and scrotal ultrasound. On CT, the appendix and the inguinal sac are best identified on sagittal cuts, although it can often be missed. Usually, the bowel is identified within the hernia sac; however, identifying the appendix definitively is difficult. If isolated scrotal pathology is suspected, then scrotal ultrasound is performed. The benefits of ultrasound include low cost and no radiation risk, but the results are operator dependant and often are sensitive for pathology but not specific.³ We did not have a chance to perform CT imaging in our center. We had a diagnosis of incarcerated hernia preoperatively and realized the certain diagnosis of Amyand hernia intraoperatively in our cases.

Repair

Losanoff and Basson divide the Amyand hernia into 4 subtypes:

- 1) A normal appearing appendix in the inguinal sac,
- 2) Inflamed appendix,
- 3) Perforation and
- 4) Complicating intraabdominal pathology (ie, abscess or malignancy).²

Each subtype has a different surgical management in which repair addresses the pathology of the appendix as well as the hernia.³ Our cases were both subtype two and we preferred to perform appendectomy and inguinal hernia repair with mesh graft at the same time. There was no contamination of purulent material, macroscopically.

Incision

The surgical approach is usually dictated by the suspected diagnosis at the time of surgery. Additionally, surgical tradition suggests that strangulated hernias should not be reduced into returning potentially necrotic bowel to the peritoneal cavity or creation of an occult incarceration via "en masse" reduction, which has been reported in the case of an Amyand's hernia. Absence of fever or leukocytosis does not guarantee absence of ischemic bowel. Thus we did not try to reduce the hernia sac in both cases. A laparotomy or diagnostic laparoscopy is initiated for suspected bowel obstruction or appendicitis. An anterior groin incision is used for suspected incarcerated inguinal hernia. As often the diagnosis is not made until the operative plan is underway, the methods of repair have varied from open repair to laparoscopic repair to a combination of both techniques. Advocates for laparoscopic repair cite facilitated reduction under direct visualization, observation of other pathologies, and minimal manipulation of friable tissues. There is also the benefit of the ability to repair bilateral hernias if present.^{3,4}

Appendectomy vs. No Appendectomy

Traditionally, when a normal-appearing appendix is found, the appendix is reduced into the abdomen, high ligation of the sac is performed, and mesh is used for repair of the hernia. When the appendix is grossly inflamed, appendectomy is performed and the defect is closed primarily with a tissue repair. In the pediatric

population, hernia repair consists mainly of high ligation of the hernia sac. Although the indications for incidental appendectomy are still present in the pediatric population, it is also argued that the appendix is beneficial for its lymphoid tissue, and its removal would be detrimental to immune development of the pediatric patient. Several authors also feel that the appendix can be useful in the future for urinary diversion or anterograde enemas. Advocates for appendectomy in the setting of a normal appearing appendix claim that subsequent procedures will be avoided, and the absence of the appendix will prevent future diagnostic difficulties.³ In both cases our patients were adult males with inflamed appendices thus we had to perform appendectomy procedure.

Mesh vs. No Mesh

Hernia repair with mesh has been shown to have a decreased incidence of recurrence when compared with native tissue repair; however, it is common practice to avoid the use of prosthetic mesh in cases considered contaminated or infected. Several authors argue that synthetic mesh can be used for the repair of the hernia defect after appendectomy although antibiotics and copious irrigation should be used.

In a 6-case report of the appendix in a femoral hernia, four of the 6 patients had inflamed appendices at the time of operation; however, all underwent appendectomy with repair of mesh. Only 1 wound infection was reported, which later experienced a recurrence. Of all the case reports, they had the longest follow-up with a mean of 6.4 years. Longterm data on recurrence in cases where tissue repair was performed is not available, although some authors speculate that the incidence of recurrence would be increased in tissue repairs created in the face of inflammation.

Current literature has supported the use of biologic materials in the contaminated or clean-contaminated setting as they have the capacity to become revascularized and to resist infection. The explanted mesh is surrounded by collagen and other stromal cells; however, it cannot be said that those cells are evidence of fascial regeneration.³ We had the only type of mesh available at our centre was polypropylene. We decided to perform hernia repairs with mesh graft as compatible with the Losano and Basson's scala, intraoperatively.

Although it was impossible to evaluate the bacterial

translocation in the inguinal area, there was no conspicuous contamination of purulent material thus we used mesh greft. Cankorkmaz *et al.*⁶ recommend that if the surgeon suspects the appendix to be ischemic in the hernia sac, a full course of therapeutic antibiotics can be helpful postoperatively, but in patients with acute appendicitis without necrosis or perforation, one dose of prophylaxis is adequate. Intravenous antibiotics were given to our patients until they were discharged from hospital and both continued antibiotherapy for 10 days peros.

Conclusion

The literature is replete with case reports of unique presentations or complications of an Amyand hernia; however, few papers focus on the outcomes after hernia repair. Most papers conclude that mesh should be avoided after appendectomy, although the authors who have had

experience in this setting report few complications. The use of biologic mesh has been shown to have a role in the setting of contaminated fields. Appendectomy via the hernia sac is the treatment of choice. Herniorrhaphy is recommended but a 50% wound infection rate can be anticipated. Wound irrigation, drainage and antibiotics would seem sensible ways of reducing wound sepsis. Most of the case reports regarding Amyand hernia fail to mention hernia recurrence after primary repair, although in many cases, the thought is that definitive repair will occur in a later operation. Repairs of incarcerated hernias should be furtherly evaluated by prospective trials. Today's knowledge shows us that cases should be evaluated individually. We report two cases of mesh graft use in a clean-contaminated field with no sign of infection or recurrence at short-term follow-up.^{2,3,7}

References

1. Cavallaro A, Lo Menzo E, Di Vita M, *et al.* Use of biological meshes for abdominal wall reconstruction in highly contaminated fields. *World J Gastroenterol* 2010;16:1928-33.
2. Losano JE, Basson MD. Amyand hernia: A classification to improve management. *Hernia* 2008; 12:325-6.
3. Burgess PL, Brockmeyer JR, Johnson, *et al.* Amyand hernia repaired with bio-a: A case report and review. *Journal of Surgical Education* 2011;68:62-6.
4. Doyle G, McCowan C. Amyand hernia: A case of an unusual inguinal herniace. *American Journal of Emergency Medicine* 2008;26: 637.
5. Kaymakci A, Akillioglu I, Akkoyun I, *et al.* Amyand's hernia: A series of 30 cases in children. *Hernia* E-pub July 22, 2009.
6. Cankorkmaz L, Ozer H, Guney C, *et al.* Surgical outcome research amyand's hernia in the children: A single center experience. *Surgery* 2010;147:140-3.
7. Hutchinson R. Amyand's hernia. *Journal of the Royal Society of Medicine* 1993;86:104-5.