

Isolated Splenic Metastasis of Colorectal Carcinoma: A Case Report

Kolorektal Karsinomun İzole Splenik Metastazı: Olgu Sunumu

Bartu Badak

Eskişehir Osmangazi University Faculty of Medicine, Department of General Surgery, Eskişehir, Turkey

ABSTRACT

Isolated splenic metastasis from colorectal carcinoma is very rare. This rareness can be explained by anatomical, histological and functional characteristics of the spleen. Most cases are asymptomatic and the diagnosis is usually made by postoperative imaging methods. There are a few cases for isolated splenic metastasis arising from colorectal carcinoma. We reported a 63 year-old man case of isolated splenic metastasis from colorectal cancer.

Keywords: Colorectal carcinoma, splenic metastasis, diagnosis

ÖZ

Kolorektal karsinomdan kaynaklanan izole splenik metastazlar çok nadirdir. Bu nadirlik dalağın anatomik, histolojik ve fonksiyonel karakteristik özellikleri ile açıklanabilmektedir. Çoğu olgular asemptomatiktir ve tanı genellikle ameliyat sonrası görüntüleme yöntemleri ile konmaktadır. Kolorektal karsinomdan kaynaklanan izole splenik metastazlı çok az olgu vardır. Biz kolorektal karsinomdan kaynaklanan izole splenik metastazlı 63 yaşında bir erkek olgu sunduk.

Anahtar Kelimeler: Kolorektal karsinom, splenik metastaz, tanı

Introduction

Colorectal carcinoma is a common malignancy worldwide. Thus metastasis of colorectal carcinoma are the most common cause of mortality. Most cases are asymptomatic and the diagnosis is usually made by postoperative imaging methods.¹ Most site of metastasis for colorectal carcinoma are liver, lungs and peritoneum.² Less commonly brain, bone and adrenals are effected organs. Isole splenic involvement as metastasis is very rare for colorectal cancers.³ Berge¹ reported the incidence of splenic metastasis as 7.1% in 7165 autopsy cases with various cancers although the incidence of splenic micrometastasis arising from colorectal carcinomas is reported as 6% (4.4%-colon, 1.6%-rectal) in 1019 colorectal tumors.⁴ Splenic tumors whether primary or metastatic, are unusual.⁵ Splenic metastasis arises about 1% of all metastasis and their most common primary sources are breast, lung, colorectal and ovarian carcinomas.⁶

Case Report

In 2011 a 63 year old man was referred to our surgery department because of abdominal pain and weight loss. There was a history of constipation, abdominal pain and weight loss for 3 months. Hemoglobin level was 13 and carcinoembryonic antigen (CEA) (3.09) and cancer 19.9 levels and other laboratory levels were in normal limits. Colonoscopy and computerized tomography (CT) showed us a polypoidal growth in sigmoid colon. The colonoscopic biopsy result was moderately differentiated adenocarcinoma. There was no distant metastasis in tomographic examination. We performed a left hemicolectomy in September 2011. Histopathological examination of the resected tumor was moderately adenocarcinoma extended up to pericolic lipoid tissue. There were no lymphatic or perinoural invasion. Sixteen reactionary lymph nodes were found. Adjuvan chemotherapy was given with regimen 5-flourourasil for



Address for Correspondence/Yazışma Adresi: Bartu Badak MD

Eskişehir Osmangazi University Faculty of Medicine, Department of General Surgery, Eskişehir, Turkey

Phone: +90 506 672 53 03 E-mail: drbartu@gmail.com

Received/Geliş Tarihi: 02.06.2016 Accepted/Kabul Tarihi: 02.07.2016

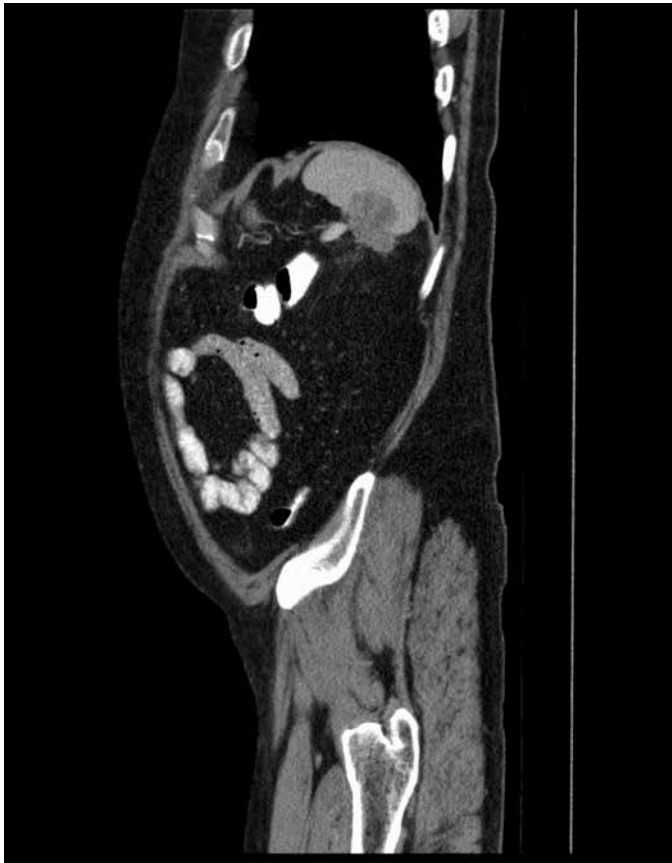

Figure 1. Computerized tomography imaging before splenectomy

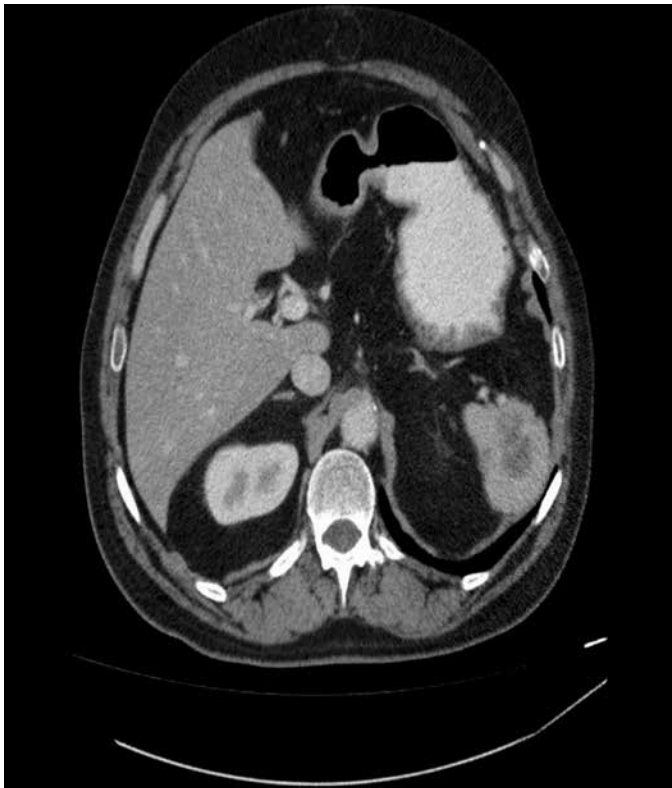


Figure 2. Computerized tomography imaging before splenectomy

6 months. He was followed every 3 months for the first year and every 6 months up to date. The patient has been disease-free for 5 years. Between 2011 and 2016 further imaging studies such as CT, abdominal ultrasonography and colonoscopy were normal yearly. But in 2016 a rising level of CEA (11.21) and a hyperdense solid mass (32*28 mm) in the spleen were found by CT. Any other remote organ metastases were not found both by CT and positron emission tomography scanning (PET) (Figure 1, 2).

Upon this a percutan tru-cut biopsy was performed to the splenic mass and confirmed the diagnosis. Histopathological examination of the specimen showed that the tumor within the spleen was a metastasis of an adenocarcinoma. Tumor cells were CK20 and CDX2 positive and CK7 negative. A splenectomy was performed in 2016. Histopathological examination of the gross specimen showed a tumor within the spleen that was a metastasis of a moderately differentiated adenocarcinoma with 3*2.5 cm dimensions. At laparotomy no recurrence and any other metastasis of solid organs and lymphadenopathy were identified.

Discussion

Colorectal cancer is a common malignancy worldwide. Thus metastasis of colorectal carcinoma are the most common cause of mortality. Most sites of metastasis for colorectal carcinoma are liver, lungs and peritoneum.² Less commonly brain, bone and adrenals are affected organs. Isolated splenic involvement as metastasis is very rare for colorectal cancers.³ Although the spleen is one of the most vascular organs and largest organ of the reticuloendothelial system; paradoxically metastasis to the spleen is very rare.⁷ The sharp angle of the splenic artery with the celiac axis, the rhythmic contraction by the sinusoidal splenic architecture, absence of afferent lymphatics and good immunosurveillance were speculated as limiting factors of metastasis.⁸ Experimental studies have shown that when the same adenocarcinoma cells are injected into the spleen, the growth rate of these cells is much lower in the spleen in comparison to the liver. Splenic tumors, whether primary or metastatic, are unusual.⁵ Splenic metastases arise in less than 1% of all metastases.⁹ Berge¹ reported the incidence of splenic metastasis as 7.1% in 7165 autopsy cases with various cancers, although the incidence of splenic micrometastasis arising from colorectal carcinomas is reported as 6% (4.4%-colon, 1.6%-rectal) in 1019 colorectal tumors.⁴ Careful autopsy examinations revealed microscopic splenic metastases up to 7-34% in cancer subjects.¹⁰

Diagnosis of splenic metastasis can be made by help of any current imaging studies such as ultrasonography, CT, PET scanning and magnetic resonance imaging.¹¹ CEA is the tumor marker most used in the follow-up of patients with colorectal cancer.¹²

Most previously described patients with splenic metastasis from colorectal carcinoma had a disease-free survival of 3-144 months after the primary tumor.¹³ Prognosis of isolated splenic metastasis and long term survival rate is still unknown in this patients.¹¹ Splenectomy and adjuvant chemotherapy seems to be the preferred treatment of isolated splenic metastases from colorectal carcinoma. However definitive conclusions cannot be drawn from the small number of case reports available. The present case is disease free during the 6 months of follow up. We therefore recommend clinicians pay close attention to the spleen for the early diagnosis of isolated splenic metastasis.

Ethics

Peer-review: Internal peer-reviewed.

References

1. Berge T. Splenic metastases. *Acta Path Micorbiol Scan* 1974;82: 499-506.
2. Jemal A, Bray F, Center MM, Ferlay J, Ward E, Forman D. Global cancer statistics. *CA Cancer J Clin* 2011;61:69-90.
3. Van Cutsem E, Olivieira J; ESMO Guidelines Working Group. Advanced colorectal cancer: ESMO clinical recommendations for diagnosis, treatment and follow-up. *Ann Oncol* 2009;20(Suppl 4):61-63.
4. Skandalakis LJ, Gray SW, Skandalakis JE. Splenic realities and curiosities. *Prob Gen Surg* 1990;7:28-32.
5. Marymont JH Jr, Gross S. Patterns of metastatic cancer in the spleen. *Am J Clin Pathol* 1963;40:58-66.
6. Comperat E, Bardier-Dupas A, Camparo P, Capron F, Charlot F. Splenic metastases: clinicopathologic presentation, differential diagnosis, and pathogenesis. *Arch Pathol Lab Med* 2007;131:965-969.
7. Dunbar W, Beahrs OH, Morlock CG. Solitary splenic metastasis incidental to rectal carcinoma: report of a case. *Mayo Clin Proc* 1969;44:40-45.
8. Capizzi PJ, Allen KB, Amerson JR, Skandalakis JE. Isolated splenic metastasis from rectal carcinoma. *South Med J* 1992;85:1003-1005.
9. Sauer J, Sobolewski K, Dommisch K. Splenic metastases-not a frequent problem, but an underestimate location of metastases; epidemiology and course. *J Cancer Res Clin Oncol* 2009;135:667-671.
10. Thomas SM, Fitzgerald JB, Pollock RE, Evans DB. Isolated splenic metastases from colon carcinoma. *Eur J Surg Oncol* 1993;19:485-490.
11. Weathers BK, Modesto VL, Gordon D. Isolated splenic metastasis from colorectal carcinoma: report of a case and review of the literature. *Dis Colon Rectum* 1999;42:1345-1348.
12. Arnaud JP, Koehl C, Adloff M. Carcinoembryonic antigen (CEA) in diagnosis and prognosis of colorectal carcinoma. *Dis Colon Rectum* 1980;23:141-144.
13. Avesani EC, Cioffi U, De Simone M, Botti F, Carrara A, Ferrero S. Synchronous isolated splenic metastasis from colon carcinoma. *Am J Clin Oncol* 2001;24:311-312.